



BioBacta

Journal of Bioscience and Applied Research
www.jbaar.org

Protective Effects of *Ambrosia maritima* and *Allium sativum* Plant Extracts on Different Tissues of Envenomed mice with *Leiurus quinquestriatus* Scorpion Venom

Nahed M. M. Emam* and Aljohara M. Al-Otaibi**

*Department of Zoology, Faculty of Science, Al Arish University, Egypt.

** Department of Biology, College of Science, Princess Nourah bint Abdulrahman University, Riyadh 13225, Saudi Arabia

*Corresponding author: Nahed Mohamed Mansour Emam, E-mail: nahedemam2018@yahoo.com

DOI: [10.21608/jbaar.2022.224732](https://doi.org/10.21608/jbaar.2022.224732)

Abstract

Background: Scorpion envenomation is a common hazard in many parts of the world and in Sinai, hence great attention must be directed towards such animals to avoid or reduce their dangers. One of the most common antioxidant medicinal plants in Sinai is the *Ambrosia maritima* or *Damsisa* plant; it is playing an important role in reducing or neutralizing the toxic effects of venoms. Also, the *Allium sativum* plant or (garlic) has been used for many years to treat a variety of medical problems. **Aim of work:** the present study was prepared to illustrate the protective effect of damsisa and garlic plant extracts in different tissues of mice envenomed with *Leiurus quinquestriatus* scorpion venom. **Materials and methods:** 48 albino mice were divided into 6 groups. Group I: the healthy control rats received tap water for 4 weeks, and then intramuscularly (i.m.) injected with saline solution and sacrificed after 48 hours from an injection. Group II: envenomed mice were intramuscularly injected with (0.15 µg/g b.wt.) dose of the scorpion venom and sacrificed after 48 hours from envenoming. Group III: mice treated with a daily oral dose of *Damsisa* plant extract (100 mg/kg) for 4 weeks; Group IV was treated with a daily oral dose of garlic plant extract (220 mg/kg) for 4 weeks. Group V: the envenomed mice were injected with the same dose of the scorpion venom and pretreated with oral doses of *Damsisa* (100 mg/kg b. wt) for 4 weeks. Group VI: the envenomed mice were injected with the same dose of the scorpion venom and pretreated with an oral dose of garlic plant extract (220 mg/kg b. wt) for 4 weeks. All mice were sacrificed after 48 hours from envenoming. At the end of the experiment, some tissues samples from skeletal muscles, testis, and lung tissues were collected for histopathological, immunohistochemical, and DNA ladder assay. **Results:** envenomed mice had severe cellular degeneration, cytoplasmic vacuolization, cellular infiltrations, and marked dilatation of blood vessels in the skeletal muscles, testis, and lung tissues. This result is confirmed with extreme immunohistochemical changes in lung tissues and the results of the DNA ladder assay revealed increased DNA fragmentation in brain tissues. The envenomed and plant-treated mice revealed marked diminished effects in histopathological alternations in the studied tissues compared to envenomed mice and reduced DNA fragmentation in brain tissues. **Conclusion:** This study concluded that *Ambrosia maritima* (D) and *Allium sativum* (G) plants have a protective effect against scorpion envenomation and especially the garlic plant showed the best results. Our results suggested that the ameliorative effects of these plant extracts may be due to the antioxidant and anti-inflammatory properties of these plants in combating free radical-induced oxidative stress and tissue injury resulting from envenomation.

Keywords: Scorpion, envenomation, *Ambrosia maritima*, *Allium sativum*, DNA fragmentation, histopathology, caspase 3

Received: January 12, 2022. Accepted: February 28, 2022. Published: March 14, 2022

1-Introduction

Scorpion envenomation is a common acute life-threatening health problem in developing countries.

Leiurus quinquestriatus is one of the dangerous scorpions all over the world and represents a health hazard in Egypt, it is moderately abundant in many places in South Sinai and Upper Egypt. It has garnered a lot of attention after the isolation of a peptide called chlorotoxin from its venom which is used for the identification and treatment of gliomas (El-Atti, 2020)¹. The scorpion venom is a heterogeneous mixture of various neurotoxins, cardiotoxins, nephrotoxins, and hemolytic that exert acute toxicological effects in humans⁽²⁾.

Scorpion venom is a complex structure composed of neurotoxic proteins, salts, acidic proteins, and organic compounds, thereby having neurologic, cardiovascular, hematologic, and renal side effects, in addition to

local effects such as redness, pain, burning, and swelling (Abd El-Aziz et al., 2019)³. The degree of envenomation is associated with several factors including scorpion species, venom lethality, a dose of venom injected at the time of the sting, and the victim's physiological response to venom (Karnad, 2009)⁴. The common symptoms in scorpion sting victims are severe pain and inflammatory reactions whereas mortality may happen in rare cases (Uawonggul et al., 2006)⁵. The synergistic impact of cardiac, respiratory, autonomic, and metabolic abnormalities in scorpion sting patients may lead to multisystem failure and death (Bawaskar and Bawaskar, 2007)⁶. The venom of *Leiurus quinquestriatus* is known to induce multiple effects on different body organs. The sting of such scorpion showed an association of central nervous system and cardiovascular manifestations that could occur at early phases of envenoming in all victims. Short-term administration of the venom significantly induced mutagenic activity, apoptotic effects at early stages of toxicity with *Leiurus quinquestriatus* venom besides

swelling, rupture, and necrosis at later stages (Cupo et al., 2007 & Emam et al., 2011)^(7,8). Scorpion's venoms are known for their harmful effects and may cause severe health problems (Veiga, et al., 2009)⁹, despite their negative effects, scorpion venoms are a rich source of bioactive ingredients that are extensively used as anti-bacterial (Amorim, 2019)¹⁰, antimicrobial (Alajmi et al., 2020)¹¹ and anti-viral agents (El-Bitar et al., 2019)¹². In addition, recent researches proved that these toxins are effective in cancer therapy (Nafie, et al., 2020)¹³ including; glioma, breast adenocarcinoma (Crusca et al., 2018)¹⁴. Toxins from the same venom have a weak effect on the cardiac sodium channel and a marked effect on rat brain and skeletal muscle sodium channel (Gordon et al., 2003)¹⁵. The scorpion α -toxin from *Leiurus quinquestriatus* is active at various mammalian voltage-gated sodium channels of skeletal and cardiac muscles (Kahn et al., 2009)¹⁶.

There are several reports of the popular use of medicinal plants against venomous creatures and snakebites around the world, especially in tropical and subtropical regions such as Asia, Africa, and South America [Dey 2012, Gomes et al., 2010]^(17,18). The rural and tribal people living in remote areas greatly depend on folk medicines for the treatment of bites from any venomous creatures [Sulochana et al., 2015]¹⁹. The use of medicinal plants against venomous creatures is a historical practice throughout human history, and this knowledge has been transferred among the rural communities from generation to generation [Butt et al., 2015]²⁰. Nowadays, these herbal antidotes used in folk traditional medicine gained much attention by toxicologists worldwide as a tool for the design of potent inhibitors against venom toxins. The potential advantages of antiophidic plants are their possible low cost, easy access, stability at room temperature, and ability to neutralize a broad spectrum of toxins, including the local tissue damage [Sulochana et al., 2015 and Butt et al., 2015]^(19,20).

Generally, the severity of envenomation encouraged many scientists to use some medicinal plants to neutralize or reduce the envenoming effects. Certain plants are believed to have curative power, where parts of these plants may be applied to the wound, eaten, or worn around the neck (Uawonggul *et al.*, 2006 & Emam *et al.*, 2013) ^(5,21). It has been also reported that aqueous extracts of 64 plant species tended to scorpion venom antidotes (Al-Asmari *et al.*, 2016) ²². However, no more available literature was found concerning the use of *damsisa* or garlic plant in the case of *Leiurus quinquestriatus* scorpion envenomation. Previous studies showed that the methanolic extract of *Ambrosia maritima* plant (family: Compositae), which is highly used in folkloric treatments in the Sinai peninsula of Egypt, can reduce the toxic effects and cytotoxic effects and tissue damage of liver, ileum, and kidney tissues in rats induced by *scorpion* venom with different doses and durations (Mansour *et al.*, 2007a; Mansour *et al.*, 2011) ^(23,8).

Allium sativum or garlic (family: Liliaceae) is one of the common plant products, traditionally used for its cytotoxic, antitumor, antifungal, antibacterial, and antiviral properties. It has been used as a traditional medicine in the treatment of heart diseases, tumors, intestinal parasites, and headaches and exhibits medicinal properties including immunomodulation, hepatoprotection, antioxidant, antimutagenic, antibacterial and anticarcinogenic, antimicrobial, antithrombotic, hypolipidemic, hypercholesterolemia, hypoglycemic, antitumor activities, and neuroprotective effects in spinal cord injury Effects (Xiao *et al.*, 2013 & Hajioun *et al.*, 2015) ^(24,25). *Allium sativum* contains various substances including minerals, carbohydrates, proteins, fats, and vitamins and the biological and pharmacological effects of this plant are mainly due to its sulfur compounds such as alliin, allicin, ajoene, and others. Garlic contains sulfur compounds, several enzymes, amino acids, and minerals such as selenium. The sulfur compounds are responsible for its medicinal effects (Emam and Al-

Otabi, 2020) ⁽²⁶⁾. One of the most biologically active compounds, allicin has antimicrobial effects against many viruses, bacteria, fungi, and parasites (Londhe *et al.*, 2017) ²⁷. Herbal medicines are effectively used for the treatment of patients with scorpion envenomation, at least 92 medicinal plants with beneficial effects for treating victims of stings of different scorpion species. These commonly used herbs spanned to 37 families whilst different parts of these plants were employed therapeutically for alleviation of envenomation symptoms. The application of leaves (41%) was preferred followed by roots (19%), whole plant (14%), and seeds (9%) (Al-Asmari, *et al.*, 2017) ⁽²⁸⁾.

The present study aimed to examine the safety of oral administration of the methanolic extract of *Ambrosia maritima* or water extract of *Allium sativum* on skeletal muscle, testis, lung, and brain tissues of mice and to find out the protective role of these two plants against the effect of *Leiurus quinquestriatus* scorpion. The skeletal muscles were selected as the scorpions usually inject their venoms into the skeletal muscles.

2-Materials and Methods

2.1 - Scorpion venom

Yellow scorpion *Leiurus quinquestriatus* (Family: Bathidae) collected from Aswan deserts, Egypt. were milked by electric chocks (110 Volts). The collected venom was freeze-dried and kept in a dissector at 4°C, then reconstituted with saline solution to prepare the required concentrations of venom dose. The venom dose of **0.15 µg/g** b.wt was intramuscularly injected according to Emam *et al.* (2013) ²¹ and the mice were sacrificed after 48 hours from envenoming.

2.2 Preparation of the plant extracts

2.2.1- *Ambrosia maritima*

The Damsisa herb or *Ambrosia maritima* (family: Compositae) was collected from South Sinai, Egypt. The whole plant was dried in dark at room temperature for two weeks then grind. The powder was refluxed with 70% methanolic alcohol for four days. The extract was evaporated at 50°C by a rotator evaporator. The residue was then weighted and suspended in distilled

water for preparation of the required dose (100 µg/g body weight) according to **Emam et al. (2011)**⁸.

2.2.2- *Allium sativum*

Fresh cloves of garlic were peeled and pulverized by an electric grinder and left overnight; then, it was filtered through cheesecloth and lyophilized to yield a dry powder (**Helal et al., 2018 & Emam and Al-Otabi, 2020**)^(29,26).

2.3 Experimental Design:

Adult healthy male mice (25-35 g body weight) were supplied from Helwan laboratory farms of the Egyptian Organization for Vaccine and Biological Preparations. Mice were fed on a standard rodent pellet diet made by the Egyptian Company for Oil and Soap and provided with tap water ad libitum. Rats were housed in metallic cages and maintained under standard conditions of temperature, humidity, and normal light/dark cycle along the experimental period. Mice were left to acclimatize for one week before starting the experiment. 48 male mice were categorized randomly into six equal experimental groups (8 mice in each group) as follows

1. Group I (C: control group): mice were treated with distilled water through gastric intubations daily for 4 weeks then intramuscularly (i.m.) injected with saline solution and dissected after 48 hours from an injection.
2. Group II (V: scorpion envenomed group): mice were intramuscularly injected with 1/3 LD₅₀ (0.15 µg/g b.wt.) dose of the scorpion venom and sacrificed after 48 hours from envenoming (**Emam et al., 2011**).
3. Group III (D: damsisa group): mice were orally pretreated with 100 mg/kg b.wt damsisa (D) plant for 4 weeks.
4. Group IV (G: garlic group): mice were orally pretreated with 220 mg/kg b. wt. garlic (G) extract for 4 weeks.
5. Group V (DV: damsisa pretreated and envenomed group): envenomed mice were orally pretreated with 100 mg/kg b.wt damsisa plant

for 4 weeks as in group III and then i.m. injected with 0.15 µg/g b.wt. dose of the venom.

6. Group VI (GV: garlic pretreated and envenomed group): envenomed mice were orally pretreated with 220 mg/kg b. wt. garlic extract for 4 weeks as in group IV and then i.m. injected with 0.15 µg/g b. wt dose of the venom. All mice were sacrificed after 48 hours from envenoming.

2.4. Histopathological and histochemical examination

Tissue specimens were fixed in 10% neutral buffered formalin dehydrated and embedded in paraffin. skeletal muscles, testis, and lung sections (5 micrometers) were cut and stained by hematoxylin and eosin for the general histological structure according to the method reported by **Bancroft and Gamble (2008)**³⁰. The slides were examined and photographed by using Carl Zeiss Axiolabre light microscope.

2.5 Immunohistochemistry Examination

Immunohistochemical detection of caspase-3 was performed by using anti caspase3 Primary antibody (Labvision, Neomarkers, USA) according to the protocol described by **Abdel-Wahab & Metwally (2015)**³¹ using a streptavidin-biotin system. Positive reaction for caspase 3 was visualized as the brown coloration of the cytoplasm in treated cells.

Quantitative analysis of immunohistochemical reactivity

Image analysis: the optical density (pixel) of the brain tissue in the present study was analyzed by using image pro. Program. An image analysis system computer-assisted was used for the measurements of the Optical density of immunoreactivity. The average of ten random fields per section was measured to obtain means for the experimental groups.

DNA Fragmentation

DNA ladder assay

DNA was isolated by using the methods of **Wu et al. (2005)** and **Gilbert et al. (2007)**^(32,33) to estimate DNA damages. 5_µg of DNA of mice was loaded separately in 1.5% agarose gel containing 1.0_µg/ml ethidium

bromide including DNA standards (0.5_μg per well) in Sub-Cell GT agarose gel electrophoresis system (BIO-RAD). After electrophoresis (45 min) gel was studied under gel doc system and was photographed through a digital camera. The DNA was visualized by placing the gel on a UV transilluminator using a DNA ladder (Jena Bioscience, Germany). The target DNA fragments images versus DNA ladder were captured and quantified using the Chemi Doc MP imager (Bio-Rad version 3, USA)

Image analysis and statistical analysis:

Image analysis was performed at the Pathology Department, National Research Center using the Leica Qwin 500 Image Analyzer (LEICA Imaging Systems Ltd, Cambridge, England,). DNA materials were calculated. The SPSS/PC program was used for statistical analysis of the results. The data were expressed as mean ± standard deviation (SD). Differences were considered statistically significant at ($P < 0.05$).

Ethical Approval

All protocols and experimental procedures were performed as per the norms of the Institutional Animal Care and Ethics Committee, AL-ARISH University, Sinai Egypt (Research protocol No (ARU-1/F/178/2020)

3-Results

Histological Investigation

Skeletal muscles (Plate 1).

Control group

The skeletal muscles of the normal mouse consisted of bundles of cylindrical multinucleated muscle fibers running parallel to each other and reflecting their characteristic muscular striation (Fig. 1).

Plant treated group

No histopathological alternations were recorded in the tissues of mice treated with the two used plant extracts under investigation. The muscle fibers showed their common parallel arrangement and characteristic cross striation. The damsisa or garlic plant treated groups did not exhibit any differences through histopathological

studies compared with a control group, and therefore the data are not presented.

Envenomed group

Skeletal muscle fibers obtained from rats envenomed with 1/3 LD50 revealed variable signs of histopathological changes. Most of the muscle fibers showed severe deterioration, loss of their cross striation, widened endomysium and invaded by numerous inflammatory cells at many regions (Fig.2). Severe deterioration of the muscle fibers was noticed in figures (3,4) that suffered from coagulative necrosis and congested blood vessels,

Plant treated and envenomed group

Administration of the venom to mice that were previously treated with the plant extract for 4 weeks exhibited amelioration of the histopathological changes induced by the venom (Figs. 5,6). Examination of the skeletal muscle's fiber obtained after 48h from envenoming with 1/3 LD50 in mice pretreated with the damsisa or garlic plant extract for 4 weeks revealed nearly normal striation of the skeletal muscle fibers with no intense histological alternations except for a few foci of myonecrosis invaded with some macrophages within the endomysium and congested blood vessel.

Testis (Plate2).

Control group

Testicular tissue of the control mice had a normal structure (Fig. 1), which is composed mainly of seminiferous tubules and interstitial tissues in between the tubules which containing Leydig cells. The seminiferous tubules are two types of cells, the Sertoli cells, resting on the thin basal lamina (tubular membrane) and the spermatogenic cells. These cells are many layers, namely, the spermatogonia, primary and secondary spermatocytes, spermatids, and finally mature spermatozoa.

Plant treated group

No histopathological alternations were recorded in the testicular tissues of mice treated with the two used plant extracts under investigation. The damsisa or

garlic plant treated groups did not exhibit any differences through histopathological studies compared with a control group, and therefore the data are not presented.

Envenomed group

Testicular tissue of envenomed group revealed variable signs of histopathological changes (Figs. 8-12). Most seminiferous tubules showed intensive degenerative changes, vacuolated cytoplasm, decreased diameters or atrophy, and highly reduced sperms in the lumen of the seminiferous tubules. Also, the spermatogenic epithelium appeared with pyknotic nuclei and vacuolated area

Moreover, widening of interstitial spaces, hemorrhage, highly reduced Leydig cells with decreased number of spermatogenic layers were commonly recorded.

Plant treated and envenomed group

Administration of the venom to mice that were previously treated with damsisa or garlic plant extract for 4 weeks exhibited amelioration of the histopathological changes induced by the venom.

Examination of the testicular tissue obtained from mice pretreated with the damsisa or garlic plant extract (Figs. 5,6) revealed remarkable regenerative features and signs of improvement in the seminiferous tubules with the reappearance of mature sperms.

Lung (Plate 3).

Control group

The lung tissue of normal mouse appeared with normal alveolar sacs, normal interalveolar septae lined with simple squamous epithelium, normal bronchioles (B) with their pseudo-stratified ciliated columnar epithelial cells (Fig. 16).

Plant treated group

No histopathological alternations were recorded in the lung tissues of mice treated with the two used plant extracts under investigation. The damsisa or garlic

plant treated groups did not exhibit any differences through histopathological studies compared with a control group, and therefore the data are not presented.

Envenomed group

Pulmonary tissues obtained from mice envenomed with 1/3 LD50 revealed variable signs of histopathological changes (Figs. 17,18). **Most bronchioles** appeared with highly delaminated epithelium and some other bronchioles contained hemolyzed blood cells or debris of degenerated cells and **the alveoli appeared with thick interalveolar septa**. Also, highly congested arteries with highly thickened and corrugated walls and cellular infiltration were detected.

Plant treated and envenomed group

Administration of the venom to mice that were previously treated with the plant extract for 4 weeks exhibited amelioration of the histopathological changes induced by the venom (Figs. 19,20). Examination of the lung tissues obtained after 48h from envenoming with 1/3 LD50 in mice pretreated with the damsisa or garlic plant extract for 4 weeks revealed less intense pathological changes although, the alveoli with thick interalveolar septa and cellular infiltration were still detected.

Immunohistochemical Observations (Plate 4 & histogram 2).

Injection of mice with scorpion venom produced an intensive amount of Caspases-3 in the pulmonary tissue (Fig..22) compared to pulmonary tissue of the control group (Fig. 21). Examination of the lung tissues obtained after 48h from envenoming with 1/3 LD50 in mice pretreated with the damsisa (DV) or garlic plant extract (GV) for 4 weeks revealed less reaction for positive immunoreactivity for anti-caspase-3 indicated by slight brown staining affinity in the lung tissue as shown in Figures 23 and 24.

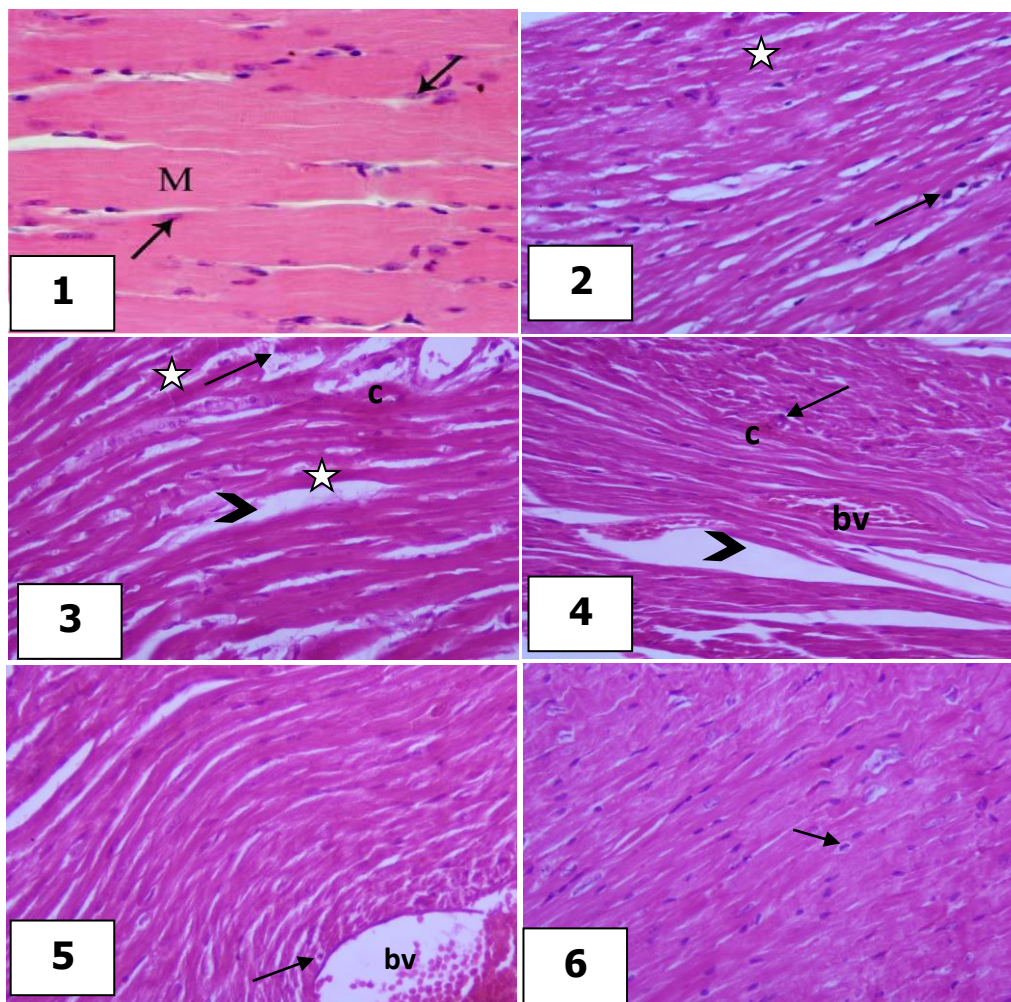


Plate 1. Photomicrographs of the skeletal muscles of mice from the control and treated groups stained with hematoxylin and eosin (H& E, X400).

Figure (1): Skeletal muscles tissues of a mouse showing normal muscle fibers (M) with cross striation and oval nuclei (arrows).

Figures (2-4): Skeletal muscles tissues of mice after 48 h. from envenoming with 1/3 LD50 showing severe deterioration of muscle tissues, numerous inflammatory cells (arrows) invading muscle fibers suffering from coagulative necrosis (c), loss of striation (stars), widened endomysium (arrowheads), and congested blood vessels (bv).

Figure (5): Skeletal muscles tissues of a mouse pretreated with damisa plant extract for 4 weeks then envenomed with 1/3 LD50 and sacrificed after 48 h from envenoming (DV) showing less intense histopathological changes and foci of necrotic fibers invaded with macrophages (arrows) and congested blood vessel (bv).

Figure (6): Skeletal muscles tissues of a mouse pretreated with garlic plant extract for 4 weeks then envenomed with 1/3LD50 and sacrificed after 48 h from envenoming (GV) showing normal striations and disappearance of histopathological changes except for a few macrophages (arrow).

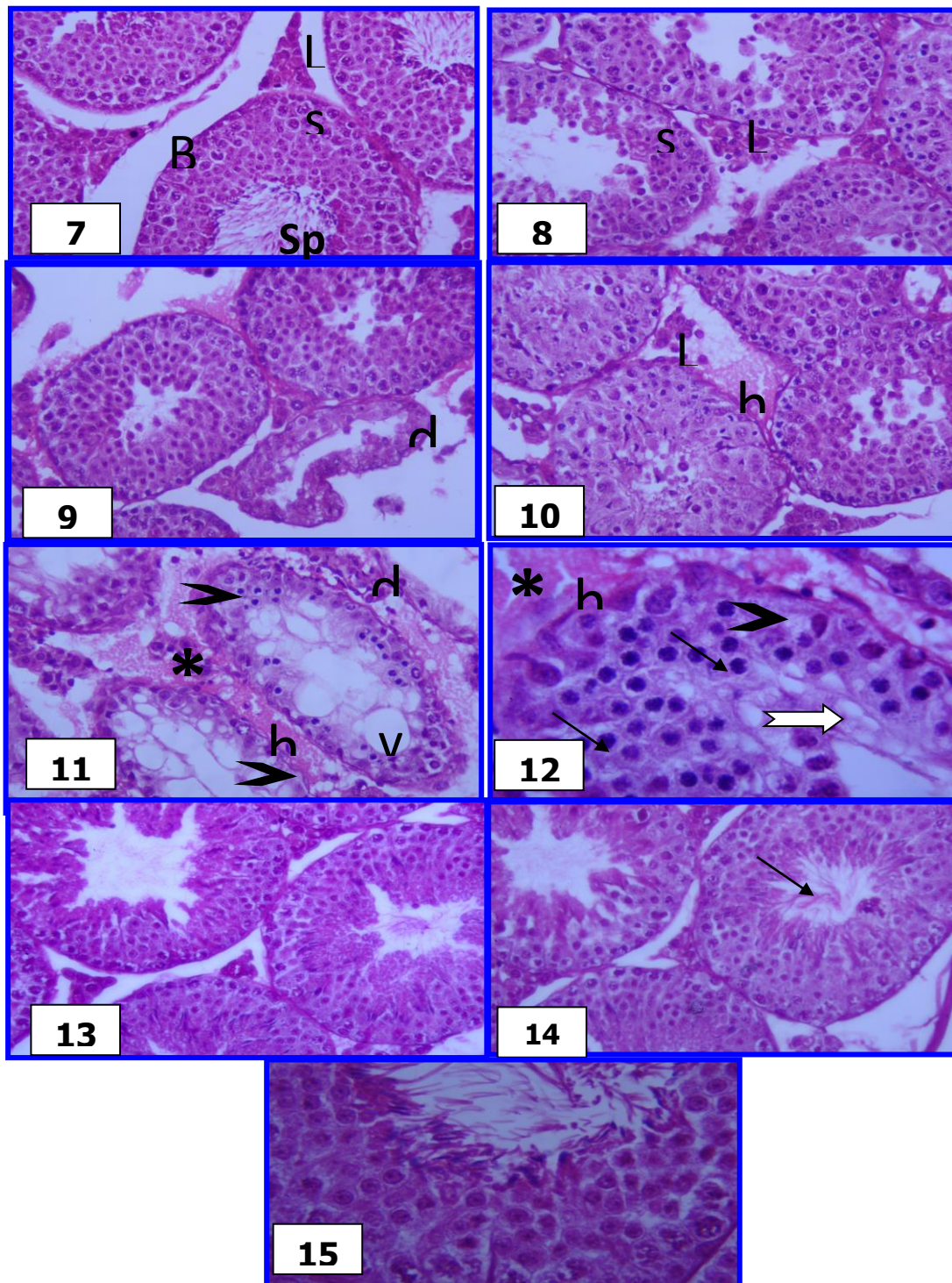


Plate 2. Photomicrographs of the testis of mice from the control and treated groups stained with hematoxylin and eosin (H&E).

Fig.7. Testicular tissue of the C group shows seminiferous tubules (S) which are surrounded by the basement membranes (B), sperms (Sp) in the lumens and interstitial tissue in between the tubules containing Leydig cells (L). (X 200). **Figs. 8-12.** Testicular tissue of envenomed group showing seminiferous tubule (S) with disorganization, degenerative changes (d), vacuolated cytoplasm (v), decreased diameters, or atrophy in some seminiferous tubules with decreased number of spermatogenic layers and highly reduced sperms in the lumen of the seminiferous tubules (arrowheads). Note: the spermatogenic epithelium appeared with pyknotic nuclei (thin arrow) and vacuolated area (thick arrow) in addition, to widening of interstitial spaces (*) with hemorrhage (h) and highly reduced Leydig cells (L) (8-10 X 200 & 11,12 X 400). **Fig.13.** Testicular tissue of (DV) group showing remarkable regenerative features (X 200). **Figs. 14 & 15.** Testicular tissues of (the GV) group showing signs of improvement in the seminiferous tubules with the reappearance of mature sperms (arrow). (X 200).

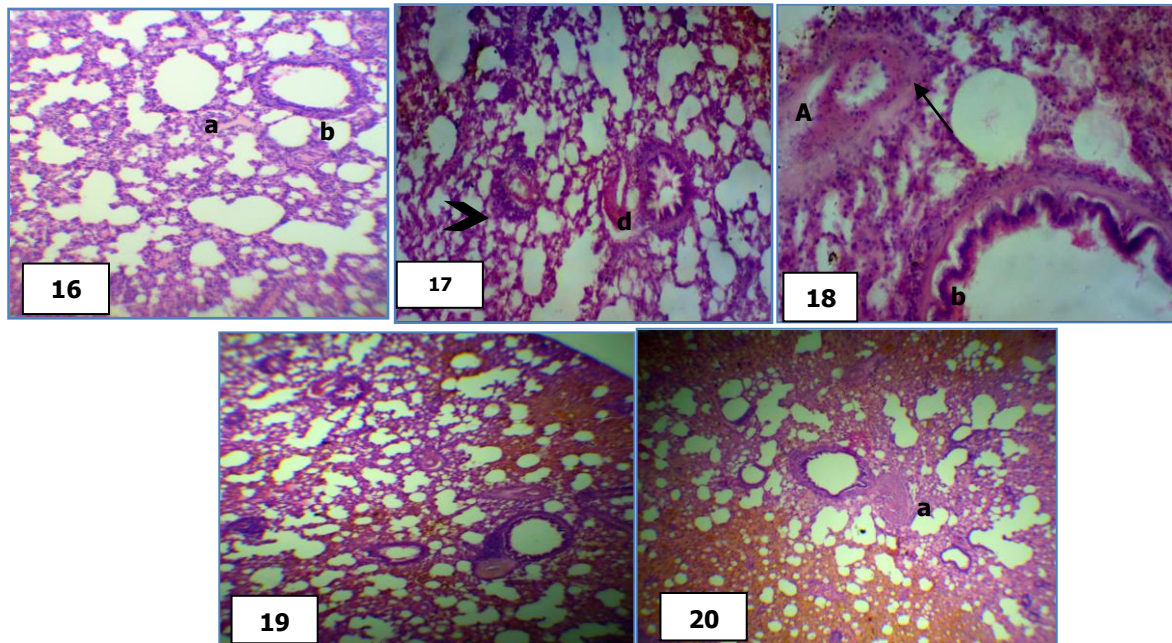


Plate 3. Photomicrographs of the lung tissues of mice from the control and treated groups stained with hematoxylin and eosin (H& E)

Fig. 16 (**control group**) showing lung tissue of a control mouse with normal alveolar sacs (a), interalveolar septae (s) lined with simple squamous epithelium, bronchioles (B) with their pseudo-stratified ciliated columnar epithelial cells, (X 250). Figs. 17 & 18 from the evenomed group showing most bronchioles (b) with highly delaminated epithelium (*) and alveoli (a) with thick interalveolar septa (s), cellular infiltration (arrow). Notice, some bronchioles contain hemolyzed blood cells (arrowhead) or debris of degenerated cells (d). Also, highly congested arteries with highly thickened and corrugated walls (A) and cellular infiltration (arrow) were detected (17: X 200, 18: X400). Figs. 19 & 20 from (DV) and (GV) groups showed less intense pathological changes although, the alveoli with thick interalveolar septa (s) and cellular infiltration (arrow) were still detected (X 200).

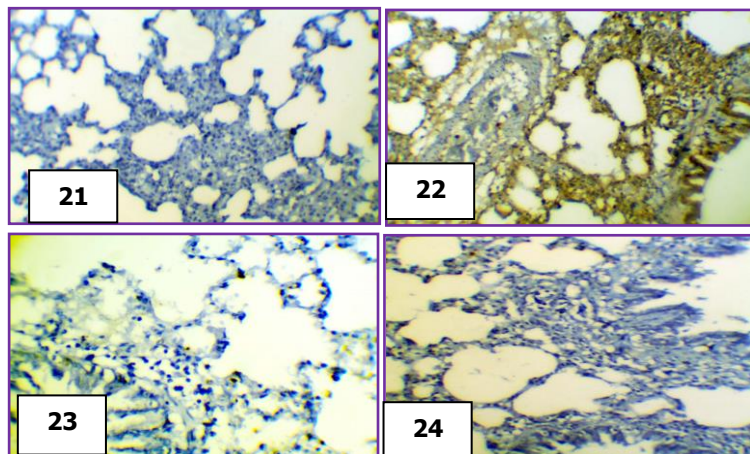
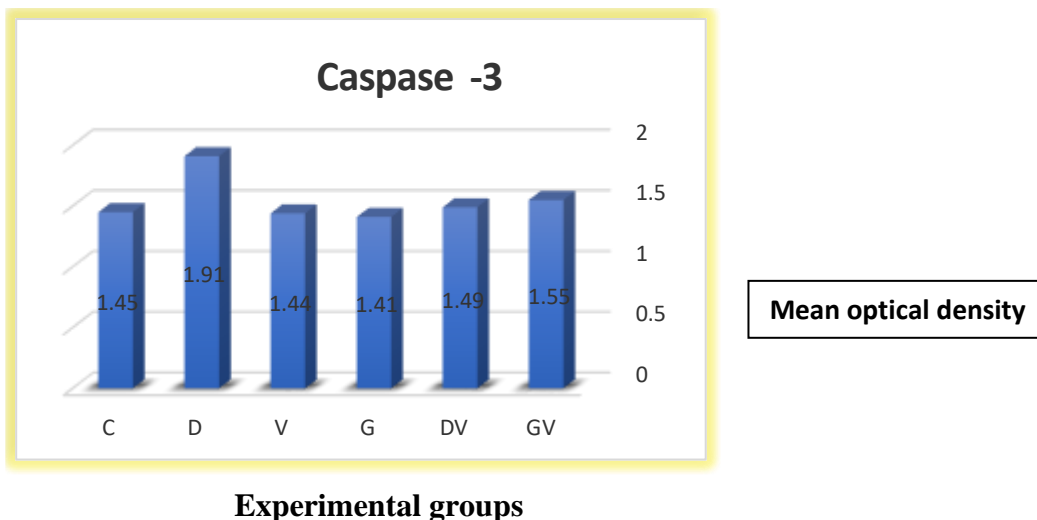


Plate 4. Photomicrographs of the lung tissues of mice from the control and treated groups stained with caspase-3 immunostaining (X200).

Fig. 21 lung tissue of a control mouse showing negatively stained caspase-3 Fig. 22-: lung tissue of an evenomed mouse showing widespread reaction for positive immunoreactivity for anti-caspase-3 indicated by less dense brown staining affinity in the lung tissue. Figs. 23-24: lung tissue of (DV) and (GV) groups showing less reaction for positive immunoreactivity for anti-caspase-3 indicated by slight brown staining affinity in the lung tissue



Histogram 2. Revealing the mean optical density (MOD) values of caspase-3 in the lung tissues of mice in experimental groups.

Significance: $P < 0.05$ (*), $P < 0.01$ (**)

2.6 DNA fragmentation

DNA ladder assay (Fig. A & histogram 1)

As shown in Fig. A, scorpion envenomation induced DNA damages. The results demonstrated that the venom-induced DNA damages in brain tissues of mice while the pretreatment of envenomed mice with Damsisa or Garlic plant extract reversed the DNA damages comparable to the control levels. The most bettered effects were demonstrated by garlic plant treatment.




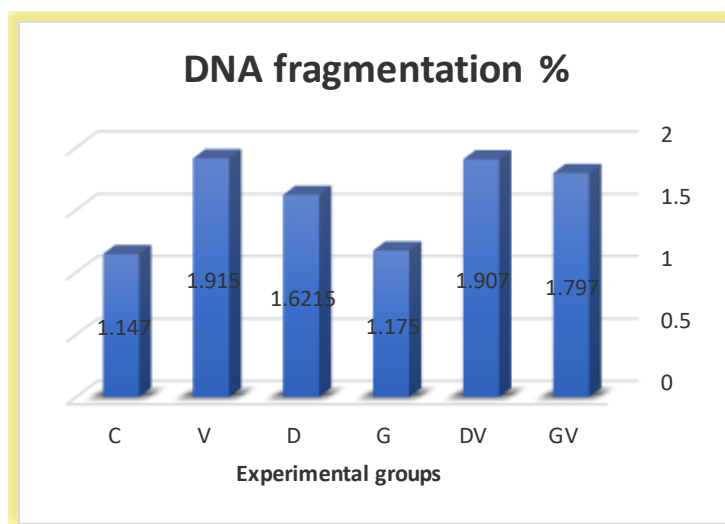
Fig. A. Agarose gel showing DNA damage by scorpion venom and preventive effect of plant extracts in different groups.

Agarose gel electrophoresis of extracted DNA from brain tissues of mice; results of the DNA fragmentation assay confirm that the treatment with damsisa plant extract or garlic plant extract attenuates scorpion venom-induced DNA damage in the brain cells of mice. Lanes (from left) high molecular weight marker (M), control (c), Scorpion venom group (V), Damsisa plant treated group (D); Garlic plant treated group (G), Damsisa pretreated and envenomed group (DV), Garlic pretreated and envenomed group (GV)

Table 1 DNA fragmentation in mice lung tissues in control and treated groups

Treatment	DNA fragmentation Mean (% ± S.D)
Control (C)	1.147± 0.029
Scorpion venom (V)	1.915**± 0.032
Garlic plant extract (G)	1.175± 0.035
Damsisa plant extract (D)	1.6215*± 0.071
Damsisa plant + Scorpion venom (DV)	1.907**± 0.098
Garlic plant extract + Scorpion venom (GV)	1.797**± 0.009

Scorpion venom group (V), Damsisa plant extract group (D); Garlic plant extract group (G), Damsisa pretreated and envenomed group (DV), Garlic pretreated and envenomed group (GV)
 Data are presented as mean ± standard deviation (n = 8 mice/treatment). ** indicate significance from the control group at P < 0.05 and P < 0.01 probability level.



Histogram 1: showing DNA fragmentation % comparison among the six studied groups (C, V, D, G, D V, and GV). Pretreatment with damsisa plant extract in envenomed mice (DV) or garlic plant extract in envenomed mice (GV) markedly suppressed the fragmentation of DNA compared to envenomed group only. Moreover, the DNA electrophoretic patterns in mice treated with garlic plant extract were more comparable to the control groups.

4-Discussion

Leiurus quinquestriatus represents one of the most dangerous species of scorpions all over the world, especially in Upper Egypt and Sinai (El-Hennawy, 2014, Saleh *et al.*, 2017 & El-Atti *et al.*, 2020) ^(34,35,1). Scorpion sting envenoming poses major public health problems, the treatments include antivenoms, chemical antidotes, and phytotherapy, with varying degrees of effectiveness and side effects (Abd El-Aziz *et al.*, 2019) ⁽³⁾. The injection of such venom to the experimental animals of the present study showed serious pathological alternations, the alterations observed due to injection of 1/3 LD₅₀ dose agree with those recorded by Mansour *et al.* (2011) ⁽⁸⁾ who used the same venom. Cellular swelling could be considered as the primary morphologic response to all forms of cell injury and could be attributed to the venom action on sodium and potassium channels of the cell membrane, which could alter the membrane permeability and induce accumulation of Na⁺ as well as the entrance of extracellular water into the cell (Emam *et al.*, 2013) ⁽²¹⁾. Neurotoxins are the main components of scorpion venom that are known to be responsible for the pathological manifestations of envenoming (Ahmadi *et al.*, 2020) ⁽³⁶⁾. Chemically, scorpion venom is a mixture of several neurotoxins, cardiotoxins, nephron toxins, hemolytic toxins, nucleotides, amino acids, oligopeptides, phospholipase-A, hyaluronidase, acetylcholine esterase, histamine, serotonin, 5-hydroxyptamine, and proteins that inhibit protease, angiotensinase, and succinate dehydrogenase (Mansour 2008 & Bawaskar and Bawaskar, 2012) ^(37,2). Furthermore, the crude venom of this scorpion-induced cytotoxicity elevated the reactive oxygen species and enhanced apoptotic pathways in some cancer cell lines (Al-Asmari, *et al.*, 2018) ⁽³⁸⁾. Oxidative stress generated in the tissues is the directing factor of toxicity (Emam *et al.*, 2020) ⁽³⁹⁾, the venom has been established to be capable of generating ROS and hydroxyl radical as well as inducing both inflammation and oxidative

stress (Emam *et al.*, 2013 & Al-Asmari, *et al.*, 2018) ^(17,38).

However, some exogenous oxidants, such as H₂O₂, will result in the overproduction of ROS, which may induce multiple cellular damages, including lipid peroxidation, nuclear DNA strand breaks, and mitochondrial alteration (Zhang *et al.*, 2010) ⁽⁴⁰⁾.

In contrast, the venom of this species has also antimicrobial activity against different types of pathogenic bacteria (Alajami *et al.*, 2020) ¹¹. Moreover, several bioactive toxins were isolated from the venom of this scorpion. For example, Bradykinin Potentiating Factor (BPF) normalized the hepatic injury induced by CCl₄ (Salman, 2018) ⁽⁴¹⁾.

The intensity of envenoming effects can also be reduced by non-specific stimulation of the immune system that would result in neutralization or phagocytosis of the venom peptides. Phospholipase enzymes play a significant role in the cascade which leads to pain and inflammatory responses, whilst, inhibition of these enzymes may relieve scorpion envenoming (Abbasi *et al.*, 2010 & Al-Asmari *et al.*, 2016) ^(42,22)

The present study was reflected the anti-venom activity of damisa and garlic plant extracts in mice and proved remarkable recovery of histology damage in skeletal muscle, testis and lung, tissues, and DNA fragmentation assay. The pretreatment with the studied plant extracts can improve the histological structure of the skeletal muscle, testis, and lung tissues of envenomed mice despite the presence of few inflammatory cells, few necrotic lesions, and lesser injuries observed in the lung tissues. The ameliorating effects of garlic are more pronounced, most areas of the lung showed normal alveolar spaces, alveolar and bronchioles with minor cell degeneration This further proves the ability of the extracts to prevent lung damage and preserve lung normal histopathology.

The role of the *Ambrosia maritima* plant in reducing the toxicity induced by the venom may be attributed to its antioxidant activity due to the presence of higher

flavonoid concentrations in the plant extract (**Ahmed and Khater, 2001, Polydoro et al., 2004**)^(43,44). **Barnes et al. (2002)**⁽⁴⁵⁾ showed that natural antioxidants could act as membrane stabilizers preventing functional damage of these membranes. **Ode and Asuzu (2006)**⁽⁴⁶⁾ also showed that the methanolic extract of the bulb of the *Crinum jagus* plant was able to significantly protect mice from death, myonecrosis, inflammation, and hemorrhage induced by the lethal effects of venoms.

In agreement with the present study, methanolic leaves extract of *Thapsia garganica* (has high antioxidant activity and is used as anti-scorpion venom) increased the survival time of mice injected with lethal doses of scorpion venom, with the remarkable recovery of histology damage and induced a significant decreased of biochemical markers of kidney, liver and heart function (**Bouimeja et al., 2018**)⁽⁴⁷⁾.

Fatani et al. (2006)⁽⁴⁸⁾ proved the protective effects of the antioxidant *Ginkgo biloba* extract against *Leiurus quinquestriatus* venom which induced tissue damage in rats. **Nabil et al. (2006)** added that the antioxidant quercetin flavonoids, which are present in the most herbal formation, could maintain the glutathione content that reacts with free radicals and terminates lipid peroxidation thereby preventing tissue damage⁽⁴⁹⁾.

Moreover, **Robaszkiewicz et al. (2007)**⁽⁵⁰⁾ proved the antioxidative effects of quercetin flavonoid (the well-known phenolic compound widely present in Compositae plants on the cells of in vitro culture at low concentrations. It has been also reported that pretreatment with grape seed proanthocyanidins offers significant protection against *Leiurus quinquestriatus* envenomation possibly via enhancement of the antioxidant defense systems (**El-Alfy et al., 2008**)⁽⁵¹⁾.

Some compounds from plants also inhibit enzymes like phospholipase A2 which is one of the main components of the scorpion venom (**Abubakar et al., 2000**)⁽⁵²⁾. In addition, the pharmacological activities of most sesquiterpene lactones (ambrosin and damsine)

isolated from the *Ambrosia maritima* plant (**Iskander et al., 2004**) may explain the present protective effect of *Ambrosia maritima* against lesions induced by the scorpion venom⁽⁵³⁾.

The reduction of the number of inflammatory cells in the scorpion envenomed rats pretreated with the plant extract supports the anti-inflammatory activities of the *Ambrosia maritima* plant. Most species of the same family were used against stings and contain compounds with anti-inflammatory properties including flavonoids, coumarins, triterpenes, sterols, and saponins (**Hutt and Houghton 1998**). **Ishikawa and Kitamura (2000)**^(54,55) suggested that bioflavonoids quercetin, which is considered as a main constituent of the plant have been regarded as the therapeutic agents for inflammatory diseases. Quercetin possesses efficient antioxidant activity and animal experiments suggest that quercetin protected the brain, liver, and other tissues against oxidative stress induced by ischemia-reperfusion injury, toxic compounds, and other factors (**Ghosh et al., 2013**). **Eleyan et al. (2018)**^(56,57) demonstrated that quercetin's protective effect may be due to its anticarcinogenic and antimutagenic properties of quercetin which considers as a pleiotropic protein kinase enzymes inhibitor (**Xingyu et al., 2016**)⁽⁵⁸⁾. Certainly, quercetin was reported as a strong anti-inflammatory substance against different inflammatory mediators that can be expressed on different cell types, in both human and experimental animals. Quercetin has a role in diminishing the histopathological signs of acute inflammation in the treated animals and can suppress leucocyte recruitment, decrease chemokine levels (**Dong et al., 2014**)⁽⁵⁹⁾.

The results of the present studies demonstrated that scorpion venom-induced DNA damages in brain tissues that revealed by DNA ladder assay. DNA fragmentation% increased by venom, was reversed towards the control levels by Damsine or Garlic extract following histopathological studies that showed that the studies two extracts reduced the incidence of tissue

lesions induced by the venom-induced oxidative damage in mice. lipid metabolites produced as a result of oxidative stress-induced DNA damages (Marnett, 2000)⁽⁶⁰⁾, In addition to a free radical attack of lipids, DNA is also continuously subjected to oxidative damage (Bouimeja *et al.*, 2018)⁽⁴⁷⁾.

The crude venom of this scorpion-induced cytotoxicity elevated the reactive oxygen species and enhanced apoptotic pathways in some cancer cell lines (Al-Asmari *et al.*, 2018)⁽³⁸⁾. The presence of phenolic compounds, flavonoids, tannins, and steroids/terpenoids might explain the bioactivity of the plant extract (Bouimeja *et al.*, 2018)⁽⁴⁷⁾.

In accordance with other antioxidant plants, administration of *Sonchus asper* plant extract significantly reduced the DNA fragmentation% which was also reacted with DNA to form the mutagenic pirimedopurinone adduct of deoxyguanosine (Khan *et al.*, 2012)⁽⁶¹⁾. The aqueous leaf extract of *Moringa oleifera* (MO) reduced intracellular ROS production, DNA fragmentation in human spermatozoa in vitro due to the antioxidant properties of MO actively maintained basic sperm functions, inhibited excess sperm free superoxide production, and preserved DNA integrity (Moichela *et al.*, 2012)⁽⁶²⁾.

A considerable number of medicinal plants used by local communities in Tabuk and the other six species in Jeddah to treat scorpion stings has been documented throughout the study period including *A. sativum* followed in Jeddah (Fakhry *et al.*, 2017)⁽⁶³⁾. These plant species have high amounts of flavonoids, total phenolic compounds, saponins, alkaloids, fatty acids, and cyclic peptides (Aldoweriej *et al.*, 2016, Martins *et al.*, 2016)^(64,65). The folklore medicinal plants contain various types of flavonoids, steroids, terpenoids, alkaloids, tannins, and coumarins that may account for their anti-venom potentials (Bin Asad *et al.*, 2011, and Mansour *et al.*, 2011)^(66,8).

Some secondary metabolites viz.-alkaloids, phenolic compounds, flavonoids, terpenoids, glycosides, fatty acids, and other metabolites are present in different

plant parts. These compounds exhibit various pharmacological activities and are being used to treat scorpion stings hence these plants may become a good source of indigenous medicines. The anti-venom activity of a plant cannot be attributed to a single active ingredient; however, the overall activity results from the synergistic effect of various constituents on various target structures such as enzymes and receptors (Mansour *et al.*, 2011)⁽⁸⁾.

Salama and Sharshar (2013) found that total protein contents and SDS-PAGE analysis of different species collected from different localities in Egypt, showed differences between the protein compositions and concentrations of different scorpion's venom. They also reported that one of the factors that may influence venom toxicity and cause variable results is environmental conditions⁽⁶⁷⁾.

Medicinal plants (such as *Artemisia absinthium* and *Allium sativum*) having antimicrobial activities in association with some of the pharmacological properties (such as anti-inflammatory and antioxidant, e.g.) could be of great value to relieve especially local effects induced by venom. In another point of view, it is possible that several related plants in folk medicine as antiophidic agents do not act directly upon venom toxins but indirectly on its symptoms. Directly by neutralizing venom toxins, or indirectly, by having some of the pharmacological activities (Silva *et al.*, 2017)⁽⁶⁸⁾. The antivenom activity of a plant cannot be attributed to a single active ingredient however the overall activity results from the synergistic effect of various constituents on various target structures such as enzymes and receptors (Mansour *et al.*, 2011)⁽⁸⁾.

Fatani *et al.* (2006)⁽⁴⁸⁾ showed that extracts of *Gingko biloba* associated with aprotinin, a protease inhibitor, protected rats against cardiovascular damage induced by the venom of *Leiurus quinquestriatus*. Mansour *et al.* (2007 b & 2011)^(69,8) showed that extracts of *Ambrosia maritima* protect against the adverse effects of *L. quinquestriatus* scorpion venom on muscular and intestinal tissue in rats. Treatment with red grape seed

against *L. quinquestriatus* venom significantly reduced mortality and improved mean arterial blood pressure, signs of conduction defects, myocardial ischemia, and infarction in rats (El-Alfy *et al.*, 2008)⁽⁵¹⁾

The mechanism by which medicinal plants neutralize the toxic venom constituents is still unknown, but many hypotheses have been proposed, such as protein precipitation, enzymatic inhibition or enzyme inactivation of classes of venom toxins, proteolytic degradation, metal chelation, antioxidant action, and a combination of these mechanisms [Gomes *et al.*, 2010]⁽¹⁸⁾. In this context, some improvements in this understanding have been achieved in the last years, using *in silico* methods (e.g., docking simulations) to analyze the interaction of compounds isolated from plants and certain classes of venom toxins such as phospholipases A₂ relevant to tissue damage [Fernandes *et al.*, 2015]⁽⁷⁰⁾.

Generally, it is very clear that pretreatment with *damsisa* extract, or a garlic extract for no more than consecutive 4 weeks is safe and can exert a considerable degree of amelioration on the histological patterns of skeletal muscles, testis, and lung of mice envenomed with *Leiurus quinquestriatus* scorpion. Further studies of plant extracts mentioned in this study are required for chemical contents and toxicity, if any, that may help to increase the efficacy of their claims.

Conclusion

In conclusion, the data mentioned in this study clearly showed that *Ambrosia maritima* and *Allium sativum* possess potential antivenom properties that can be utilized for the treatment of scorpion sting victims. Both studied plants could protect the tissues against the deleterious effects induced due to envenoming with *Leiurus quinquestriatus* scorpion venom. The information reported above could be helpful for scientists, drug designers, medicinal plant boards, and other scientific bodies related to herbal research in scorpion sting treatment.

Further studies are required to identify the phytochemicals responsible for the anti-scorpion venom activity of these medicinal plants. Additionally, well-designed pharmacological and clinical trials will help in confirmation of the efficacy of the reported plants. There is also a need to create more public awareness about growing the medicinal plants in the residential vicinity so that they can be used for providing first aid to alleviate the symptoms of scorpion envenomation.

5-References

1. El-Atti M., El-Qassas, J., Gadel-Rab A., Desouky, M.(2020): *Morphology, histology, histochemistry and fine structure of venom apparatus of the medically relevant Scorpion, Leiurus quinquestriatus*. Bioscience Research 17. ((2)):1274-1288
2. Bawaskar, H.S. and Bawaskar, P.H (2012). Scorpion sting: update. JAPI 60, 46–55.
3. Abd El-Aziz FE, El-Shehaby DM, Elghazaly SA, Hetta HF 2019. Toxicological and El-Atti et al. Venom Apparatus of the Medically Relevant Scorpion, *Leiurus quinquestriatus*. Bioscience Research, 2020 ,17(2): 1274-1288 1286
4. Karnad, D.R., 2009. Management of scorpion envenomation: need for a standard treatment protocol using drugs and antivenom. J. Assoc. Phys. India 57, 299–300.
5. Uawonggul, N., Chaveerach, A., Thammasirirak, S., Arkaravichien, T., Chuachan, C., Daduang, S., 2006. Screening of plants acting against *Heterometrus laoticus* scorpion venom activity on fibroblast cell lysis. J. Ethnopharmacol. 103, 201–207.
6. Bawaskar, H.S., Bawaskar, P.H., 2007. Utility of scorpion antivenin in the management of severe *Mesobuthus tamulus* (Indian red scorpion) envenoming at rural setting. JAPI 55, 14–21.

7. Cupo P, Figueiredo AB, Filho AP, et al. Acute left ventricular dysfunction of severe scorpion envenomation is related to myocardial perfusion disturbance. *Int J Cardiol.* 2007; 116:98–106
8. Emam, N.M.; Tawfik, M.N.; Yaseen, A.E. and Rahmy, T.R. 2011. Protective role of *ambrosia maritima* plant extract against alterations induced by *leiurus quinquestriatus* scorpion venom on skeletal muscles and intestinal tissues of rats. *Egyptian Journal of Natural Toxins*, Vol. 8(1,2): 81-103.
9. Veiga ABG, Berger M, Guimarães JA, 2009. *Lonomia obliqua* venom: Pharmacotoxicological effects and biotechnological perspectives. In: De Lima, M. E., Pimenta, A. M. C., Martin Eauclaire, M. F., Zingali, R. B., RoCHAT, H. (Eds.), *Anim. Toxin: State of the Art: Perspectives in Health and Biotechnol.* UFMG, Belo Horizonte, pp. 372-390.
10. Amorim B, Daniele-Silva AMS, Parente AA, Furtado E, Carvalho JWF, Oliveira EC, Santos MS, Silva SRB, Silva A, Silva J, Monteiro MF, Fernandes-pedrosa MF, 2019. Potent and broad-spectrum antimicrobial activity of analogs from the scorpion peptide stigmurin, *Int. J. Mol. Sci.*, 20: 1-21.
11. Alajmi R, Al-ghamdi S, Barakat I, Mahmoud A, Abdon N, Abdel Baber IA, 2020. Antimicrobial activity of two novel venoms from Saudi Arabian scorpions: *L. quinquestriatus* and *A. crassicauda*. *Int. J. Pept. Res. Ther.*, 26: 67-74
12. El-Bitar AMH, Sarhan M, Abdel-Rahman MA, Quintero-Hernandez V, Aoki-Utsubo C, Moustafa MA, Possani LD, Hotta H, 2019. Smp76, a scorpine-like peptide isolated from the venom of the scorpion *Scorpio maurus palmatus*, with potent antiviral activity against hepatitis C Virus and Dengue Virus. *Internat. J. Pept. Res. Therap.*, First Online: 06 July 2019
13. Nafie MS, Abdel Daim MM, Ali IAI, Nabil ZA, Tantawy MA, Abel-Rahman MA, 2020. Antitumor efficacy of the Egyptian Scorpion Venom *Androctonus australis*: in vitro and in vivo study. *JoBAZ*, 8: 8.
14. Crusca EJR, Basso LGM, Altei WF, Marchetto R, 2018. Biophysical characterization and antitumor activity of synthetic Pantinin peptides from scorpion's venom. *Biochem. Biophys. Acta Biomembr.*, 1860, 11: 2155-2165
15. Gordon, D.; Ilan, N.; Zilberberg, N.; Gilles, N.; Urbach, D.; Cohen, L.; Karbat, I.; Froy, O.; Gaathon, A.; Kallen, R.G.; Benveniste, M. and Gurevitz, M. (2003): An 'Old World' scorpion beta-toxin that recognizes both insect and mammalian sodium channels. *Eur. J. Biochem.*, 270(12): 2663-2670.
16. Kahn, R.; Karbat, I.; Ilan, N.; Cohen, L.; Sokolov, S.; Catterall, W.A.; Gordon, D. and Gurevitz, M. (2009): Molecular Requirements for Recognition of Brain Voltage-gated Sodium Channels by Scorpion α -Toxins. *J. Biol. Chem.*, 284(31): 20684–20691.
17. Dey A., N. Phytopharmacology of antiophidian botanicals 2012. A review. *International Journal of Pharmacology*;8(2):62–79. DOI: 10.3923/ijp.2012.62.79.
18. Gomes A., Das R., Sarkhel S., et al. 2010. Herbs and herbal constituents active against snake bite. *Indian Journal of Experimental Biology.*; 48(9):865–878. [[PubMed](#)] [[Google Scholar](#)]
19. Sulochana A., Raveendran D., Krishnamma A., Oommen O.2015. Ethnomedicinal plants

- used for snake envenomation by folk traditional practitioners from Kallar forest region of Southwestern Ghats, Kerala, India. *Journal of Intercultural Ethnopharmacology*. 4(1): p. 47. DOI: 10.5455/jice.20141010122750.
20. Butt M. A., Ahmad M., Fatima A., et al. 2015. Ethnomedicinal uses of plants for the treatment of snake and scorpion bite in Northern Pakistan. *Journal of Ethnopharmacology*.; 168:164–181. DOI: 10.1016/j.jep.2015.03.045
21. Emam, M.; Mahmoud, H. and Ibrahim, M. 2013. Ameliorated effects of *Allium sativum* (garlic) on hepatic and renal tissues of envenomed mice with *Leiurus quinquestriatus* scorpion venom. *Archives Des Sciences Journal* 66 (7), 227-248.
22. Al-Asmari, A., Manthiri, R., Abdo N., Al-Duaiji F., Khan, H. 2016. Saudi medicinal plants for the treatment of scorpion sting envenomation. *Saudi Journal of Biological Sciences*, 10.:1-8
23. Mansour, N.M.; Tawfik, M.N.; Yaseen, A.E. and Rahmy, T.R. 2007a. Prophylactic effect of *Ambrosia maritima* plant extract on hepatic tissues of rats envenomed with *Leiurus quinquestriatus* scorpion. *Egy. J. Nat. Tox.*, 4(2): 69-100.
24. Xiao, J., Ching YP., Liong, E.C., Nanji, A.A., Fung, M.L. & Tipoe, G.L. 2013. Garlic-derived S-allylmercaptocysteine is a hepatoprotective agent in non-alcoholic fatty liver disease in vivo animal model. *Eur J Nutr*, 52(1), 179-191.
25. Hajioun, B.; Jowhari, H. and Mokhtari, M. 2014. Effects of cell phone radiation on the levels of T3, T4 and TSH, and histological changes in thyroid gland in rats treated with *Allium sativum* extract. *African Journal of Biotechnology* 13, 163-169
26. Emam, N.M. and Al-Otobi, A. M. 2020. Hepatoprotective effects of *Allium sativum*, *Trigonella foenum-graecum* and *Brassica oleracea* antioxidant plant extracts against pathological changes induced in hyperthyroid rats. *Jokull Journal*, 70(2):26-48.
27. Londhe, V. P.; Gavasane, A.T. and Nipate, S.S. 2017. Role of garlic (*Allium sativum*) in various diseases: an overview. *Journal of Pharmaceutical Research and Opinion* 4, 129- 134.
28. Al-Asmari, A., Manthiri, R., Abdo N., Al-Duaiji F., Khan, H. 2017. Saudi medicinal plants for the treatment of scorpion sting envenomation *Saudi J Biol Sci* 2017 Sep; 24(6):1204-1211.
29. Helal, E.; El Sayed, R.; Ebrahiem, S. and Mustafa, M. A. 2018. Effect of *Trigonella*, *Allium sativum* and their mixture on some physiological parameters in hyperthyroidimic Rats. *The Egyptian Journal of Hospital Medicine* 71 (4), 3049-3055
30. Bancroft, J. and Gamble, A. 2008. *Theory and practice of histology techniques*. 6th ed, Churchill Livingstone. New York, London, 83-92
31. Abdel-Wahab, B.A., & Metwally, M.E. 2015. Clozapine-induced cardiotoxicity: role of oxidative stress, tumour necrosis factor alpha and NF- κ B. *Cardiovascular toxicology*, 15, 355-365.
32. Gilbert MT, Haselkorn T, Bunce M, Sanchez JJ, Lucas SB, Jewell LD, Van Marck E, Worobey M. 2007. The isolation of nucleic acids from fixed, paraffin-embedded tissues, which methods are useful when? *PLoS ONE* ;2(June (6)): e537
33. Wu B, Ootani A, Iwakiri R, Sakata Y, Fujise T, Amemori S, Yokoyama F, Tsunada S,

- Fujimoto K. T.2005. Cell deficiency leads to liver carcinogenesis in azoxymethane treated rats. *Exp Biol Med*; 231:91–8.
34. El-Hennawy, H. K. (2014). Updated List of Scorpions of Egypt. *Serket*, 1–4.
35. Saleh M., Younes, M., Badry, A. and Sarhan, M. 2017: Zoogeographical analysis of the Egyptian scorpion fauna. *Al Azhar Bulletin of Science*, 28 (1):1- 14.
36. Ahmadi, S., Knerr J., Argemi,L., Karla C. , Bordon F., et al. 2020. Scorpion Venom: Detriments and Benefits. *Biomedicines*, 8, 118; DOI:10.3390/biomedicines8050118
37. Mansour, N. M 2008. Histological and cytogenetic studies on the effect of *Ambrosia maritima* plant from Sinai on different tissues of rats envenomed with *Leiurus quinquestriatus* scorpion. Ph.D. Thesis, Zoology Department, Faculty of Science.Suez Canal University, Ismailia, Egypt.
38. Al-Asmari AK, Riyasdeen A, Islam M, 2018. Scorpion venom causes apoptosis by increasing reactive oxygen species and cell cycle arrest in MDA-MB-231 and HCT-8 cancer cell lines. *J. Evidence-Based Integr. Medic.*, 23: 3-8.
39. Emam, N., Anjum, S., Okail, H., Ibrahim, M. and Ahmad, T. 2020. Pomegranate peel extract protects against carbon tetrachloride-induced nephrotoxicity in mice through increasing antioxidants status. *Biomedical Reports.*; 13. (13): 1-9.
40. Zhang, C., Liu, C., Li, D., Yao, N., Yuan, X., Yu, A., Ma, X. 2010. Intracellular redox imbalance and extracellular amino acid metabolic abnormality contribute to arsenic-induced developmental retardation in mouse preimplantation embryos. *Journal of Cellular Physiology*, 222(2), 444-455. DOI: 10.1002/jcp.21966
41. Salman MMA, 2018. Antioxidant Effects of Bradykinin Potentiating Factor (BPF) Isolated from scorpion venom in liver injury induced by carbon tetrachloride (CCl4) in male albino rats. *J. Clin. Toxicol.*, 8, 6: 399.
42. Abbasi, A.M., Khan, M.A., Ahmad, M., Zafar, M., Jahan, S., Sultana, S., 2010. Ethnopharmacological application of medicinal plants to cure skin diseases and in folk cosmetics among the tribal communities of North-West Frontier Province, Pakistan. *J. Ethnopharmacol.* 128, 322–335.
43. Ahmed, M.B. and Khater M.R. 2001. Evaluation of the protective potential of *Ambrosia maritima* extract on acetaminophen induced liver damage. *J. Ethnopharmacol.*, 75(2-3): 169-174.
44. Polydoro, M.; De Souza, K.C.; Andrades, M.E.; Da Silva, E.G., Bonatto, F.; Heydrich, J.; Dal-Pizzol, F.; Schapoval, E.E.S.; Bassani, V.L. and Moreira, J. C.F. 2004. Antioxidant, a prooxidant and cytotoxic effects of *Achyrocline satureioides* extracts. *Life Sci.*, 74(23): 2815-2826.
45. Barnes, J.; Anderson, L.A.; Phillipson, J.D. 2002. "Herbal Medicines: A guide for Healthcare Professionals". 2nd ed. Pharmaceutical Press, London.
46. Ode, O.J. and Asuzu, I.U. 2006. The anti-snake venom activities of the methanolic extract of the bulb of *Crinum jagus* (Amaryllidaceae). *Toxicon*, 48(3): 331-342.
47. Bouimeja, B., El Hidan, M. Touloun, O. Laaradia, M. et al. 2018. Anti-scorpion venom activity of *Thapsia garganica* methanolic extract: Histopathological and biochemical evidence. *J Ethnopharmacol.* 2018 Jan 30; 211:340-347.
48. Fatani, A.J., Al Zuhair, H.A., Yaquob, H.I., et al., 2006. Protective effects of the antioxidant

- Ginkgo biloba extract and the protease inhibitor aprotinin against *Leirus quinquestriatus* scorpion venom-induced tissue damage in rats. *J. Venom. Anim. Toxins. Incl. Trop. Dis.* 12, 255-275
49. Nabil, Z.I.; Hussein, A.A.; Youssef, A.A.; Ahmed, S.H. and Omran, A.A. 2006. Assessment of the therapeutic effect of Calotropis procera extract compared to Digoxin on myocardial pathophysiology: An experimental study. *Egy. J. Nat. Toxins.*, 3: 51-76.
 50. Robaszekiewicz, A.; Balcerczyk, A. and Bartosz, G. 2007. Antioxidative and prooxidative effects of quercetin on A549 cells. *Cell Bio. Int.*, 31(10): 1245-1250.
 51. El-Alfy, A.T., Ahmed, A.A., Fatani, A.J., Kader, F., 2008. Amelioration of the cardiovascular manifestations of the yellow scorpion *Leiurus quinquestriatus* envenomation in rats by red grape seeds proanthocyanidins. *Toxicon* 51, 321–333.
 52. Abubakar, M.S.; Sule, M.I.; Pateh, U.U.; Abdurahman, E.M.; Haruna, A.K. and Jahun, B.M. 2000. *In vitro* snake venom detoxifying action of the leaf extract of *Guiera senegalensis*. *J. Ethnopharmacol.*, 69: 253-257.
 53. 3-Iskander, G.M.; Modawi, B.M.; Ahmed, H.E.; Elmer, O.; Schlemper, E.O. and Duddeck, H. 2004. Crystal and molecular structure of ambrosin and damsins, sesquiterpene lactone isolates of *Ambrosia maritima*. *J. für. Praktische. Chemie.*, 330(2): 182-190.
 54. Hutt, M.J., and Houghton, P.J. 1998. A survey from the literature of plants used to treat scorpion stings. *J. Ethnopharmacol.*, 60(2): 97-110.
 55. Ishikawa, Y. and Kitamura, M. 2000. Bioflavonoid quercetin inhibits mitosis and apoptosis of glomerular cells *in vitro* and *in vivo*. *M. Biochem. Biophys. Res. Commun.*, 279(2): 629- 634.
 56. Ghosh, A., Sarkar, S., Mandal, A. K., & Das, N. 2013. Neuroprotective Role of Nanoencapsulated Quercetin in Combating Ischemia-Reperfusion Induced Neuronal Damage in Young and Aged Rats. *PLoS One*, 8(4), e57735. DOI: 10.1371/journal.pone.0057735
 57. Eleyan, M, El-Desouky, M., Ibrahim, K.; Daboun, H. and Abd El Rahman, H. 2018. Quercetin alleviates the adverse effects of nano-rich diesel exhaust particles on pregnancy and fetal growth in rats. *Research article bioscience research*, 15(4): 4590-4602.
 58. Xingyu, Z., Peijie, M., Dan, P., Youg, W., Daojun, W., Xinzheng, C., Yangrong, S. 2016. Quercetin suppresses lung cancer growth by targeting Aurora B kinase. *Cancer medicine*, 5(11), 3156-3165. doi:10.1002/cam4.891
 59. Dong, Y., Wang, J.-., Feng, D., Qin, H., Wen, H., Yin, Z., Li, C. 2014. Protective effect of quercetin against oxidative stress and brain edema in an experimental rat model of subarachnoid hemorrhage. *International journal of medical sciences*, 11(3), 282-290. doi:10.7150/ijms.7634
 60. Marnett, J.L.2000. Oxyradicals and DNA damage. *Carcinogenesis* 2000, 21: 361–70.
 61. Khan, R. Khan, M., Sahreen, S. 2012. Protective effect of *Sonchus asper* extracts against experimentally induced lung injuries in rats: A novel study *Experimental and Toxicologic Pathology* , 64; 7-8
 62. Moichela, F., Adefolaju, G., Henkel, R., Opuwari, C.2021. Aqueous leaf extract of *Moringa oleifera* reduced intracellular ROS

- production, DNA fragmentation and acrosome reaction in human spermatozoa in vitro. *Andrologia*, 53(1): e13903 DOI: 10.1111/and.13903. Epub 2020 Nov 22.
63. Fakhry, A. Migahid, M. and Anazi, H. 2017. Herbal remedies used in the treatment of scorpion stings in Saudi Arabia. *Global Journal of Medicinal Plant Research*, 5(1): 1-8.
64. Aldoweriej, A.M., K.B. Alharbi, E.M.A. Saeed and I.M. El-Ashmawy, 2016. Anti-microbial activity of various extracts from some plants native to Alqassim Region, Saudi Arabia *Journal of Food, Agriculture & Environment*, 14: 14-19.
65. Martins, N., and S. Petropoulos, 2016. Chemical composition and bioactive compounds of garlic (*Allium sativum* L.) as affected by pre-and post-harvest conditions: A review. *Food Chemistry*, 211: 41-50.
66. Bin Asad, M.H.H., G. Murtaza, S. Siraj, S.A. Khan, S. Azhar, M.S. Hussain, T. Ismail, M.S. Hussain, I. Hussain, 2011. Enlisting the scientifically unnoticed medicinal plants of Pakistan as a source of novel therapeutic agents showing anti-venom activity. *African J. Pharm. Pharmacol.*, 5: 2292-2305
67. Salama, W.M. and K.M.S. Harshar, 2013. Surveillance study on scorpion species in Egypt and comparison of their crude venom protein profiles. *The Journal of Basic & Applied Zoology*, 66: 76-86. Amal, M. Fakhry, 2 Masarrat, M. A.
68. Silva, J., Junior, A Zucolotto, S. and Pedrosa, M. 2017. Medicinal Plants for the Treatment of Local Tissue Damage Induced by Snake Venoms: An Overview from Traditional Use to Pharmacological Evidence. *Evid Based Complement Alternat Med*. 2017; 2017: 5748256. DOI: 10.1155/2017/5748256
69. Mansour, N.M., Tawfik, M.N., Rahmy, T.R., and Yaseen, A.E., 2007. Prophylactic effect of *Ambrosia maritima* plant extract on renal tissues of rats envenomed with *Leiurus quinquestriatus* scorpion. *Egy. J. Nat. Tox.* 4, 101-130.
70. Fernandes C. A. H., Cardoso F. F., Cavalcante W. G. L., *et al.* 2015. Structural basis for the inhibition of a phospholipase A₂-like toxin by caffeic and aristolochic acids. *PLoS ONE*. 2015;10(7) DOI: 10.1371/journal.pone.0133370.e0133370